

Neural systems for recognizing emotion

Ralph Adolphs

Recognition of emotion draws on a distributed set of structures that include the occipitotemporal neocortex, amygdala, orbitofrontal cortex and right frontoparietal cortices. Recognition of fear may draw especially on the amygdala and the detection of disgust may rely on the insula and basal ganglia. Two important mechanisms for recognition of emotions are the construction of a simulation of the observed emotion in the perceiver, and the modulation of sensory cortices via top-down influences.

Addresses

Division of Cognitive Neuroscience, Department of Neurology,
200 Hawkins Drive, University of Iowa College of Medicine, Iowa City,
Iowa 52242, USA; e-mail: ralph-adolphs@uiowa.edu;
website: <http://www.medicine.uiowa.edu/adolphs>

Current Opinion in Neurobiology 2002, 12:XXX–XXX

0959-4388/02/\$ – see front matter

© 2002 Elsevier Science Ltd. All rights reserved.

DOI 10.1016/S0959-4388(02)00301-X

Abbreviation

fMRI functional magnetic resonance imaging

Introduction

Emotional signals, either visual or auditory, can be considered as aspects of both an emotional response and social communication. There are multiple schemes for categorizing emotions (Table 1). This review focuses on so-called basic emotions that can be most reliably recognized from facial expressions: happiness, surprise, fear, anger, disgust, and sadness. Most brain structures that participate in the recognition of basic emotions involve both perceptual processing—identifying the geometric configuration of facial features in order to discriminate among different stimuli on the basis of their appearance—and recognition of the emotional meaning of a stimulus—knowing that a certain expression signals fear. Recognition relies on disparate strategies. For instance, recognition of fear from a facial expression may occur by linking the perceptual properties of the facial stimulus to various knowledge-based processes. These include the knowledge components of the concept of fear, the lexical label ‘fear’, the perception of the emotional fear response (or a central representation thereof) that the stimulus triggers in the subject, or knowledge about the motor representations required to produce the expression shown in the stimulus [1•].

Recognition of emotion from facial expressions

A large number of different structures participate in recognizing the emotion shown in a face: the occipitotemporal cortices, amygdala, orbitofrontal cortex, basal ganglia, and right parietal cortices, among others. These structures are engaged in multiple processes and at various points

in time, making it difficult to assign a single function to a structure (Figure 1).

Visual cortices

Regions of the occipital and posterior temporal visual cortices play a critical role in perceptual processing of socially and emotionally relevant visual stimuli. Single-unit studies in monkeys, intracranial field potential studies in neurosurgical human patients [2–4] and functional imaging studies, have all provided evidence that cortical areas in the lateral parts of the inferior occipital gyrus, fusiform gyrus, and superior temporal gyrus are disproportionately important in face processing [5•,6•,7]. The cortex around the fusiform gyrus is activated more by the sight of faces than by the sight of other objects or scrambled faces, and has consequently been dubbed the ‘fusiform face area’ [8,9]. However, it is also activated when subjects engage in computationally similar processing of non-face stimuli that involves subordinate-level categorization (e.g. when subjects are asked to name a picture of a pelican as ‘pelican’ rather than simply as ‘bird’; the former requires a level of categorization that is subordinate to the latter) [10]. Furthermore, even though one can identify regions of maximal activation in response to particular stimulus classes, processing of different categories of visual stimulus, including faces, in fact engages distributed regions of visual cortex in specific patterns [11•].

Although perceptual processing of faces draws on a collection of visual cortical regions, there is evidence that the fusiform gyrus is especially involved in representing the static features of faces, and consequently in contributing to encoding identity, whereas the superior temporal gyrus is especially involved in representing the dynamic, changeable features of faces, and therefore in contributing to encoding facial expression and direction of gaze [6•,7,12]. Furthermore, although the construction of a detailed perceptual representation of a face appears to require ~170 ms within these cortical regions, some rapid, coarse categorization of gender and emotion can occur with substantially shorter latencies. This presumably indicates the existence of cruder perceptual routes that occur in parallel to routes for the full structural encoding of the stimulus. The earliest activity that discriminates between emotional facial expressions is seen in midline occipital cortex as early as 80 ms [13] to 110 ms [14]. Monkey single-unit recordings have provided evidence that neurons in temporal cortex encode information about faces variably with time. Although information sufficient to distinguish faces from other objects is encoded in ~120 ms, responses encoding fine-grained, subordinate, information sufficient to distinguish different emotional expressions only appear ~170 ms [15] (these latencies would be somewhat longer in humans). These findings suggest the possibility that

Table 1**Classification schemes for emotion.**

Behavioral states	Motivational state	Moods, background emotions	Emotion systems [94]	Basic emotions	Social emotions
Approach	Reward	Depression	Seeking	Happiness	Pride
Withdrawal	Punishment	Anxiety	Panic	Fear	Embarrassment
	Thirst	Mania	Rage	Anger	Guilt
	Hunger	Cheerfulness	Fear	Disgust	Shame
	Pain	Contentment		Sadness	Maternal love
	Craving	Worry		(Surprise)	Sexual love
				(Contempt)	Infatuation
					Admiration
					Jealousy

Emotions are situated in a continuum of response classifications. The more primitive classes, towards the left, pertain to emotional reactions, whereas the more complex classes, towards the right, pertain to social communication. Typically, researchers working on animals have adopted a scheme relying on reward and punishment, whereas research in humans has often used so-called 'basic' emotions, and psychiatric or social psychological studies have utilized even more complex constructs such as the 'social' emotions, whose neural underpinnings are at present very poorly understood. Reproduced with permission from [1••].

responses to emotional stimuli in visual cortices are modulated by feedback, perhaps from structures such as the amygdala and orbitofrontal cortex (see below).

The amygdala

The amygdala participates in the recognition of emotional signals via at least two classes of input mechanisms: a subcortical route via the superior colliculus and the pulvinar thalamus, and a cortical route via the visual neocortex. Structures in the subcortical route are activated both when normal subjects are shown subliminal facial expressions of fear [16], and when subjects with blindsight, due to striate cortex damage, discriminate emotional facial expressions [17,18•]. Subliminally presented facial expressions of fear activate the amygdala in normal subjects [19], and give an exaggerated amygdala response in individuals with post-traumatic stress disorder [20]. Electrophysiological responses in the human amygdala to emotional facial expressions are first seen ~120 ms [21], and probably show differential effects as a function of emotion category at ~150 ms [22].

Human lesion studies have consistently found impaired recognition of emotional facial expressions following bilateral amygdala damage, often disproportionate for fear [23–25,26•,27,28], but sometimes encompassing multiple negative emotions, including fear, anger, disgust, and sadness [29,30,31••]. There is debate regarding the interpretation of these findings. It has been argued that the amygdala is principally involved in processing stimuli related to threat and danger [29,32•], that it triggers cognitive resources to help resolve ambiguity in the environment [33], or that the emotions whose recognition depends most on the amygdala are related to behavioral withdrawal [34].

Unilateral damage to the amygdala generally results in more subtle impairments. An impaired ability to learn new emotional facial expressions correlated with the extent of unilateral amygdala damage [35], and two studies [34,36] found that subjects with damage to the right amygdala

were impaired, as a group, in their recognition of negative emotions from facial expressions. It is important to keep in mind that the patients in these studies also had damage to the temporal polar cortex and the rhinal cortex, structures bidirectionally connected with the amygdala.

Functional imaging studies have corroborated the notion that the amygdala is activated disproportionately by facial expressions of fear [37,38,39•,40]. However, such activation appears to depend on relatively passive or implicit processing of the emotion: perceptual processing of facial expressions of fear can activate the amygdala, whereas requiring subjects to label the emotion can instead result in deactivation [41] and concomitant suppression of emotional psychophysiological responses [42]. The reduction of amygdala responses to emotional facial expressions, when the demand for explicit emotion recognition is increased, is a common observation across studies [43•] and may be mediated by the amygdala's inhibition by frontal cortex. There is also evidence for lateralized amygdala activations. Most functional imaging studies have reported left amygdala activation when subjects were shown facial expressions of emotion. The right amygdala may be activated more in response to subliminally presented stimuli [44], a finding perhaps related to the right and left amygdala's proposed contribution to dynamic versus sustained emotional evaluation, respectively [45], and reflecting the complex changes in activation over time [46]. Amygdala activations to fearful faces have also been examined in children. Some studies failed to find the same activations as seen in adults [47]. However, others reported that activation appears most robust prior to adolescence, followed by a post-adolescent shift from amygdala-mediated processing to frontal lobe-mediated processing in females [48], as well as a later general decline of amygdala activation with increasing age [49].

Orbitofrontal cortex

Damage to the orbitofrontal cortex, especially on the right, can result in impaired recognition of emotions from the

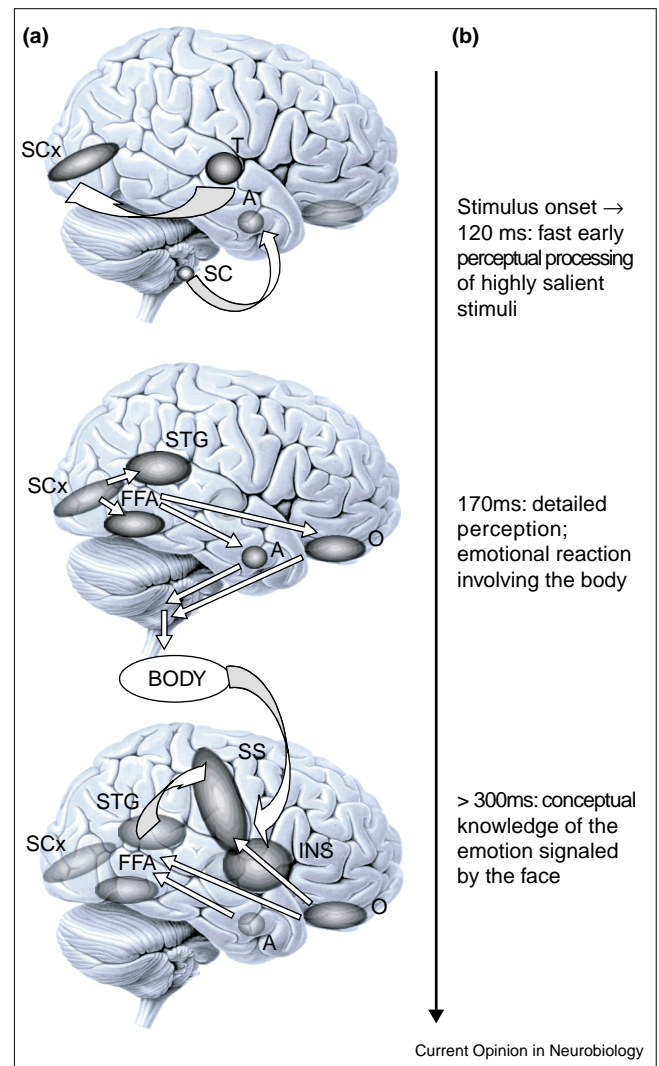
face and the voice [50]. These findings are consistent with the activation found in right orbitofrontal cortex when comparing presentations of fearful and neutral faces [51**]. In contrast to the amygdala's activation in response to passive viewing of emotional faces or gender judgements, prefrontal regions may be activated when subjects are engaged in a cognitive task requiring explicit identification of the emotion [52,53]. Disruption of processing within medial prefrontal cortex with transcranial magnetic stimulation produces longer reaction times in response to morphs of angry facial expressions, but not in response to happy facial expressions [54*]. A role for prefrontal cortex in the recognition of anger is also supported by the finding of increased activation in orbitofrontal and anterior cingulate cortex, when subjects were shown facial expressions of anger, but not of sadness [55].

Some intriguing preliminary data come from electrophysiological recordings in two patients, who had depth electrodes implanted in right prefrontal cortex for the purpose of monitoring epilepsy. In one patient, field potentials showed selectivity for faces over objects in the right inferior frontal gyrus ~ 150 ms [56]. Behavioral performance in labeling facial expressions of emotion was assessed in the same patient after surgical resection of right prefrontal cortex, and revealed a severe impairment that was relatively selective for expressions of fear. In another patient, single-unit responses were obtained in right ventromedial prefrontal cortex in response to presentation of facial expressions of fear and happiness; neuronal discrimination between the two emotions first appeared after 120 ms [57]. These findings suggest that sectors of orbitofrontal cortex, like the amygdala, can exhibit very rapid responses to emotionally salient stimuli, and that they are consequently in a position to modulate even relatively early aspects of perceptual processing via top-down influences.

Somatosensory related cortices and the basal ganglia

Following a large number of lesion studies that demonstrated a role for right frontoparietal cortices in emotion recognition, an investigation of the association between lesion location and facial emotion recognition provided evidence that somatosensory related cortices in the right hemisphere played a critical role [58*]. The study revealed a consistent pattern for all emotions: lesions in the right ventral primary and secondary somatosensory areas, and, to a lesser extent in the insula and anterior supramarginal gyrus, compromised emotion recognition. One interpretation of these findings is that viewing facial expressions of emotion triggers an emotional response in the perceiver that mirrors the emotion shown in the stimulus [59], and that representing this emotional response in somatosensory cortices in turn provides information about the emotion. This idea, that knowledge of other people's emotions may rely on simulating the observed emotion, is consistent with several other findings in humans and monkeys (see review

Figure 1



Processing of emotional facial expressions as a function of time. **(a)** Structures involved in emotion recognition at various time points. A, amygdala; FFA, fusiform face area; INS, insula; O, orbitofrontal cortex; SC, superior colliculus; SCx, striate cortex; SS, somatosensory cortex; STG, superior temporal gyrus; T, thalamus. **(b)** Time course of emotion recognition, from the onset of the stimulus at the top, through perception to final recognition of the emotion at the bottom. Attempts to localize the perception/recognition of the stimulus in space or in time suffer from the fact that the same brain structures participate in different components of processing at different points in time. Many of the mechanisms outlined here may be shared when recognizing emotion from other classes of stimuli, such as prosody. Reproduced with permission from [1**].

by Rizzolatti, this issue, and [1**] for details). It may also be related to the finding that recognition of sad facial expressions is impaired with the administration of beta blockers, which attenuate a subject's autonomic emotional reaction to stimuli [60].

Functional imaging studies have not directly corroborated the above findings, but have instead provided evidence that the insular cortex — a visceral somatosensory

cortex — is activated when subjects process facial expressions of disgust [28,40,61,62]. Two lesion cases fit with this finding. First, a patient with damage to the left insula and basal ganglia showed pronounced impairments both in the ability to recognize facial expressions of disgust and in the ability to experience the emotion himself [63••]. Second, another patient with bilateral damage to the insula, in addition to extensive temporal lobe damage, was severely impaired in the ability to recognize and experience disgust from all types of stimuli [64•]. In addition to the insula, there is good evidence that recognition of disgust requires the integrity of the basal ganglia as well as the integrity of other somatosensory related cortices in the right hemisphere [58•], indicating a distributed neural network for processing this emotion.

Some additional insights into the role of the basal ganglia in emotion recognition are offered by diseases that preferentially damage certain sectors of the basal ganglia [28]. Subjects with obsessive–compulsive disorder are impaired disproportionately in the recognition of facial expressions of disgust [65]. The evidence regarding Parkinson's disease is less decisive: although some studies have reported impaired recognition of facial emotion in Parkinson's disease, others have failed to find any such impairment [66]. The best evidence comes from Huntington's disease, which results in a disproportionate impairment in recognizing disgust from facial expressions [67], possibly prior to the onset of any other symptoms [68].

Summary of recognizing emotion from faces

Upon presentation of an emotionally meaningful stimulus, one might envision a first, feed-forward sweep of information processing. This would proceed along occipital and temporal neocortices and extract perceptual information from faces and, after ~100 ms in humans, would coarsely categorize the stimulus as expressing an emotion or not, on the basis of the structural properties of the image. Amygdala and orbitofrontal cortices could participate in the processes of emotion recognition from the face in at least three distinct ways. First, they may modulate perceptual representations via feedback. This mechanism might contribute, in particular, to fine-tuning the categorization of the facial expression and to the allocation of attention to certain of its features. The existence of such a mechanism is supported by the discovery of field potentials in human temporal visual cortex that are modulated by emotional or social information [4], and by the modulation of visual attention by emotional stimuli (in the attentional blink paradigm) that requires the amygdala [69•]. Second, the amygdala and orbitofrontal cortices may trigger associated knowledge, via projections to other regions of neocortex and to the hippocampal formation. This mechanism might contribute especially to retrieval of conceptual knowledge about the emotion. Third, they may generate an emotional response in the subject, via connections to motor structures, hypothalamus, and brainstem nuclei, where components of an emotional response to the facial expression can be

activated. This mechanism might contribute to the generation of knowledge about another person's emotional state, via the process of simulation, and would draw on somatosensory related cortices in the right hemisphere for representing the emotional changes in the perceiver. However, it is probable that the simulation of another's emotion could proceed via the generation of a somatosensory image of the associated body state, even in the absence of actual motor mimicry.

Recognition of emotion from prosody

Studies with computer-generated stimuli have provided evidence supporting two theories of emotion recognition from the patterns of stress and intonation during speech. First, data corroborate the idea that one or two simple auditory cues can be used by subjects to provide much of the information about the emotion in a prosodic stimulus, such as Fo range and amplitude variation. Second, findings also verify that the total number of cues available that can influence emotion judgements is large and features complex interactions [70]. In general, recognizing emotions from prosody alone is more difficult than recognizing emotion from facial expressions. Certain emotions, such as disgust, can be recognized only very poorly from prosody; the resulting lower statistical power in detecting possible impairments is one reason that less is known about the neural substrates of emotional prosody recognition. As with recognition of facial affect, the right hemisphere has been found to be disproportionately important for perceiving and recognizing emotional prosody in most studies [71–73], but there appears to be substantial bilateral processing as well [71,72,74,75]. In particular, the recognition of emotion from the voice draws on multiple prosodic cues, which are, in turn, processed by systems that are neuroanatomically partly segregated towards one or the other hemisphere. Right lateralized processing of the voice occurs already at the level of auditory cortex [76], and normal prosodic processing can occur despite severely impaired processing of propositional speech in global aphasia [77].

Analogous to the processing of visual social stimuli, there appear to be auditory cortical regions surrounding the primary auditory cortex that may be relatively specialized for processing more complex features of stimuli [78], including species-specific vocal signals [79]. Right frontoparietal regions consistently emerge as critical for recognition across multiple studies [50,72,80••,81], a role they may play in tandem with the basal ganglia [81]. Affective processing of auditory stimuli, other than prosody, has been shown to engage more orbital regions of the prefrontal cortex [82,83]. The evidence for the amygdala's involvement in recognition of emotion from prosody is less clear. Although a few functional imaging studies have reported amygdala activation to emotional auditory stimuli [40,71], and one lesion study reported impaired recognition of emotional prosody following bilateral amygdala damage [84], other functional imaging [85•] and lesion studies [86,87] have failed to find the same impairment.

Box 1**Current debates**

There is debate concerning the role of amygdala and other structures in the selective recognition of certain emotions, notably fear. A recent study [95**] found that recognition of fear was less accurate than recognition of other emotions, even in normal subjects. When this general difficulty was accounted for in the analysis, subjects with damage to the amygdala or right parietal cortex were, in fact, not impaired disproportionately in their recognition of fear. However, these findings depended on the use of a labeling task, in which fear was relatively more ambiguous than other labels, because it could be confused with surprise. If the confusion between 'fear' and 'surprise' is scored as incorrect, one obtains an erroneous performance score, due to the mistake of assuming that all labeling choices are equally discriminable, when in fact they are not. Although this study [95**] raises a caveat, the large number of lesion and functional imaging studies, taken together, argue strongly for neural systems that are relatively specialized for processing certain emotions (especially fear and disgust, [1**,28]).

Another issue open to question concerns the extent to which the systems reviewed here might be specialized for processing complex social stimuli, such as facial expressions. Possibly, their function is better construed in more basic terms, by linking perception of stimuli with their punishing or rewarding contingencies, a primary mechanism that would also be utilized in the recognition of complex social stimuli (c.f. [88] for such a scheme). On the other hand, the diversity of different categories of social knowledge to which social stimuli need to be linked seems to surpass the complexity of non-social processing. An alternate scheme might envision some structures, such as the amygdala and ventral striatum, implementing more basic reward/punishment associations, and other structures, notably regions of prefrontal cortex, implementing a further refinement that permits differentiation among different social stimuli and within different social contexts. Such a hierarchical arrangement might also fit best with both evolutionary and developmental accounts of emotion recognition.

Taken together then, the studies to date point to the following conclusions. First, recognizing emotional prosody draws on multiple structures distributed between both left and right hemispheres. Second, the roles of these structures are not all equal, but may be most apparent in processing specific auditory features that provide cues for recognizing the emotion. Third, despite the distributed nature of the processing, the right hemisphere, and in particular right inferior frontal regions, appear to be the most critical component of the system, working together with more posterior regions in the right hemisphere, left frontal regions, and subcortical structures.

Recognizing emotion in other sensory modalities

Our understanding of the neural correlates of emotion recognition in sensory modalities other than vision and audition is rudimentary, in large part because none of the studies have directly investigated recognition. Single-cell responses in animals have been reported to emotionally salient olfactory and gustatory stimuli especially in amygdala and orbitofrontal cortex (see [88] for review). Olfactory [85*,89,90] and gustatory [91] stimuli have been found to activate the human amygdala when they are highly aversive, likely reflecting the elicitation of a strong emotional response to such stimuli. Pleasant touch sensations have also been reported to activate orbitofrontal cortex [92].

Conclusions and future directions

Some open questions regarding emotion recognition are indicated in Box 1. Although the recognition of emotion from facial expressions has been extensively investigated, little is known about the neural structures participating in recognition of emotion from other visual cues, such as body posture, from auditory cues, or from the integration of cues from multiple sensory modalities. Likewise, next to nothing is known about the neural basis of recognizing 'social' emotions (Table 1). Explorations of the phylogeny

and ontogeny of emotion recognition, of its difference between genders [93] and between different individuals, all have important implications for our understanding of how humans and other animals regulate their social behavior. An important tool in fostering cross-talk between these varied approaches would be the further development of a uniform set of emotional stimuli and tasks that could be applied across species, to infants and adults, and in behavioral, lesion, and functional imaging studies.

Update

In humans, the emotional reactions that can be triggered by stimuli also play a role in complex aesthetic judgements. Building on lesion studies that have shown dissociations between identifying melodies or recognizing emotion from music [96], a recent functional imaging study found that highly emotional music, which resulted in 'shivers down the spine' in the listener, activated a set of paralimbic structures including the ventral striatum, amygdala, and orbitofrontal cortex [97]. Just how to categorize the emotion triggered by such stimuli remains a challenging issue, as it appears distinct from mere happiness.

Another brain structure, the ventral striatum, long known to participate in motivated behavior, has recently also been linked to complex emotional and social judgements. Judgements of the attractiveness of female faces modulated activation of the ventral striatum in a functional magnetic resonance imaging (fMRI) study; interestingly, this modulation also depended on the direction of eye gaze of the stimulus [98].

In another fMRI study [99], activation of the ventral striatum by faces was shown to depend primarily on the incentive, motivational value of the face — assessed by the viewer's amount of work in pressing a button to prolong the viewing time of the face on the screen — rather than the judged attractiveness of the face — assessed by asking the viewer to rate the attractiveness. This finding supports

the idea that motivational and aesthetic value of stimuli can be dissociated.

Acknowledgements

The author is supported, in part, by grants from the National Institute of Mental Health, National Institute of Neurological Disorders and Stroke, the EJLB Foundation and the Klingenstein Fund.

References and recommended reading

Papers of particular interest, published within the annual period of review, have been highlighted as:

- of special interest
- of outstanding interest

1. Adolphs R: **Recognizing emotion from facial expressions: psychological and neurological mechanisms.** *Behav Cognit Neurosci Rev* 2002, 1:21-61.

A comprehensive review of the various processes that contribute to the recognition of emotion from facial expressions, covering both psychological aspects and the neural structures involved.

2. Allison T, Puce A, Spencer D, McCarthy G: **Electrophysiological studies of human face perception. I. Potentials generated in occipitotemporal cortex by face and non-face stimuli.** *Cereb Cortex* 1999, 9:415-430.
 3. McCarthy G, Puce A, Belger A, Allison T: **Electrophysiological studies of human face perception. II. Response properties of face-specific potentials generated in occipitotemporal cortex.** *Cereb Cortex* 1999, 9:431-444.
 4. Puce A, Allison T, McCarthy G: **Electrophysiological studies of human face perception. III. Effects of top-down processing on face-specific potentials.** *Cereb Cortex* 1999, 9:445-458.
 5. Allison T, Puce A, McCarthy G: **Social perception from visual cues: role of the STS region.** *Trends Cognit Sci* 2000, 4:267-278.
- The authors of this review include the findings from [2-4] on electrophysiological recordings in neurosurgical patients. The authors find evidence for an assembly of multiple cortical regions within and surrounding the superior temporal sulcus that appear relatively specialized for encoding complex visual stimuli, including biologically salient stimuli such as faces and eyes.
6. Haxby JV, Hoffman EA, Gobbini MI: **The distributed human neural system for face perception.** *Trends Cognit Sci* 2000, 4:223-233.
- Here, the authors review their functional imaging data, which lends support to a scheme in which the cortex in lateral occipital regions first processes information about faces, the cortex in the fusiform gyrus then processes static feature information, and the cortex in the superior temporal gyrus processes dynamic feature information. The fusiform and superior temporal gyrus could thus contribute disproportionately to encoding information about face identity and facial expression, respectively.
7. Haxby JV, Hoffman EA, Gobbini MI: **Human neural systems for face recognition and social communication.** *Biol Psychiatry* 2002, in press.
 8. Kanwisher N: **Domain specificity in face perception.** *Nat Neurosci* 2000, 3:759-763.
 9. Kanwisher N, McDermott J, Chun MM: **The fusiform face area: a module in human extrastriate cortex specialized for face perception.** *J Neurosci* 1997, 17:4302-4311.
 10. Tarr MJ, Gauthier I: **FFA: a flexible fusiform area for subordinate-level visual processing automatized by expertise.** *Nat Neurosci* 2000, 3:764-769.
 11. Haxby JV, Gobbini MI, Furey ML, Ishai A, Schouten JL, Pietrini P: **Distributed and overlapping representation of faces and objects in ventral temporal cortex.** *Science* 2001, 293:2425-2429.

An important recent paper regarding two aspects of recognition. First, the authors demonstrate that cortical regions in ventral temporal cortex respond to multiple categories of visual stimuli, even though they may show a maximal response to a specific category, such as faces. Second, they show that stimuli from a particular category elicit reliable but complex patterns of activation across multiple regions. It thus appears that activity in a distributed mosaic of cortex in the ventral temporal lobe participates in constructing representations of categories of visual stimuli.

12. Hoffman EA, Haxby JV: **Distinct representations of eye gaze and identity in the distributed human neural system for face perception.** *Nat Neurosci* 2000, 3:80-84.

13. Pizzagalli D, Regard M, Lehmann D: **Rapid emotional face processing in the human right and left brain hemispheres: an ERP study.** *Neuroreport* 1999, 10:2691-2698.
 14. Halgren E, Raji T, Marinkovic K, Jousmaki V, Hari R: **Cognitive response profile of the human fusiform face area as determined by MEG.** *Cereb Cortex* 2000, 10:69-81.
 15. Sugase Y, Yamane S, Ueno S, Kawano K: **Global and fine information coded by single neurons in the temporal visual cortex.** *Nature* 1999, 400:869-872.
 16. Morris JS, Ohman A, Dolan RJ: **A subcortical pathway to the right amygdala mediating 'unseen' fear.** *Proc Natl Acad Sci USA* 1999, 96:1680-1685.
 17. de Gelder B, Vroomen J, Pourtois G, Weiskrantz L: **Non-conscious recognition of affect in the absence of striate cortex.** *Neuroreport* 1999, 10:3759-3763.
 18. Morris JS, deGelder B, Weiskrantz L, Dolan RJ: **Differential extrageniculostriate and amygdala responses to presentation of emotional faces in a cortically blind field.** *Brain* 2001, 124:1241-1252.
- Building on the surprising finding that a subject with blindsight was able to give above-chance discrimination of emotional facial expressions, the authors of this study use fMRI imaging to investigate the neural correlates of such blindsighted emotion perception. They find activation in a pathway from the superior colliculus to the pulvinar to the amygdala that may be the substrate of the residual visual abilities in this patient's blind visual field. The study complements findings from normal individuals, who also appear to activate this pathway when shown facial expressions of emotion under subliminal presentation [16,19].
19. Whalen PJ, Rauch SL, Etcoff NL, McInerney SC, Lee MB, Jenike MA: **Masked presentations of emotional facial expressions modulate amygdala activity without explicit knowledge.** *J Neurosci* 1998, 18:411-418.
 20. Rauch SL, Whalen PJ, Shin LM, McInerney SC, Macklin ML, Lasko NB, Orr SP, Pitman RK: **Exaggerated amygdala response to masked facial stimuli in posttraumatic stress disorder: a functional MRI study.** *Biol Psychiatry* 2000, 47:769-776.
 21. Halgren E, Baudena P, Heit G, Clarke JM, Marinkovic K: **Spatiotemporal stages in face and word processing. I. Depth-recorded potentials in the human occipital, temporal and parietal lobes.** *J Physiol* 1994, 88:1-50.
 22. Liu L, Ioannides AA, Streit M: **Single trial analysis of neurophysiological correlates of the recognition of complex objects and facial expressions of emotion.** *Brain Topogr* 1999, 11:291-303.
 23. Adolphs R, Tranel D, Damasio H, Damasio AR: **Fear and the human amygdala.** *J Neurosci* 1995, 15:5879-5892.
 24. Broks P, Young AW, Maratos EJ, Coffey PJ, Calder AJ, Isaac C, Mayes AR, Hodges JR, Montaldi D, Cezayirli E *et al.*: **Face processing impairments after encephalitis: amygdala damage and recognition of fear.** *Neuropsychologia* 1998, 36:59-70.
 25. Calder AJ, Young AW, Rowland D, Perrett DI, Hodges JR, Etcoff NL: **Facial emotion recognition after bilateral amygdala damage: differentially severe impairment of fear.** *Cognit Neuropsychol* 1996, 13:699-745.
 26. Anderson AK, Phelps EA: **Expression without recognition: contributions of the human amygdala to emotional communication.** *Psychol Sci* 2000, 11:106-111.
- Anderson and Phelps present the case of a patient with bilateral amygdala damage, who was impaired in recognizing emotional facial expressions of fear – like other subjects with bilateral amygdala damage – but was nonetheless able to produce normal facial expressions of fear on her own face. In this study, the patient made the facial expressions of fear to command; it would be interesting in future studies to see whether she would also show normal facial expressions of fear spontaneously when she actually feels afraid.
27. Sprengelmeyer R, Young AW, Schroeder U, Grossenbacher PG, Federlein J, Buttner T, Przuntek H: **Knowing no fear.** *Proc R Soc London Ser B* 1999, 266:2451-2456.
 28. Calder AJ, Lawrence AD, Young AW: **Neuropsychology of fear and loathing.** *Nat Rev Neurosci* 2001, 2:352-363.
 29. Adolphs R, Tranel D, Hamann S, Young A, Calder A, Anderson A, Phelps E, Lee GP, Damasio AR: **Recognition of facial emotion in**

nine subjects with bilateral amygdala damage. *Neuropsychologia* 1999, **37**:1111-1117.

30. Adolphs R: **The human amygdala and emotion.** *Neuroscientist* 1999, **5**:125-137.
31. Schmolck H, Squire LR: **Impaired perception of facial emotions following bilateral damage to the anterior temporal lobe.** *Neuropsychologia* 2001, **15**:30-38.
- The authors of this study find impaired recognition of multiple negative emotional expressions in two subjects with complete bilateral amygdala damage following encephalitis. The study is important because the same two subjects were previously reported to perform normally, if their data were analyzed in a standard way (as in [23,29]), but were found to be impaired when the data were reanalyzed a different way. These results show that different subjects with bilateral amygdala damage may be impaired in subtly different ways that require careful analysis of their data; notably the pattern of impairment in these two subjects is different to the pattern of impairment reported in other subjects [23,32*].
32. Adolphs R, Tranel D: **Emotion recognition and the human amygdala.** In *The Amygdala. A Functional Analysis*. Edited by Aggleton JP. London: Oxford University Press; 2000:587-630.
- A comprehensive summary of all the different emotion processing tasks that have been administered to a rare subject, who has complete, yet relatively selective, bilateral amygdala damage. We review her ability to recognize emotions from a variety of different stimuli.
33. Whalen PJ: **Fear, vigilance, and ambiguity: initial neuroimaging studies of the human amygdala.** *Curr Dir Psychol Sci* 1999, **7**:177-187.
34. Anderson AK, Spencer DD, Fulbright RK, Phelps EA: **Contribution of the anteromedial temporal lobes to the evaluation of facial emotion.** *Neuropsychologia* 2000, **14**:526-536.
35. Boucsein K, Weniger G, Mursch K, Steinhoff BJ, Irlle E: **Amygdala lesion in temporal lobe epilepsy subjects impairs associative learning of emotional facial expressions.** *Neuropsychologia* 2001, **39**:231-236.
36. Adolphs R, Tranel D, Damasio H: **Emotion recognition from faces and prosody following temporal lobectomy.** *Neuropsychologia* 2001, **15**:396-404.
37. Morris JS, Frith CD, Perrett DI, Rowland D, Young AW, Calder AJ, Dolan RJ: **A differential neural response in the human amygdala to fearful and happy facial expressions.** *Nature* 1996, **383**:812-815.
38. Breiter HC, Etcoff NL, Whalen PJ, Kennedy WA, Rauch SL, Buckner RL, Strauss MM, Hyman SE, Rosen BR: **Response and habituation of the human amygdala during visual processing of facial expression.** *Neuron* 1996, **17**:875-887.
39. Whalen PJ, Shin LM, Mclnerney SC, Fischer H, Wright CI, Rauch SL: **A functional MRI study of human amygdala responses to facial expressions of fear versus anger.** *Emotion* 2001, **1**:70-83.
- Whalen *et al.* provide a clear demonstration that the amygdala is activated by facial expressions of fear but not anger, and support the idea that it may be engaged in processing stimuli that are ambiguous with respect to the source of potential threat [33].
40. Phillips ML, Young AW, Scott SK, Calder AJ, Andrew C, Giampietro V, Williams SCR, Bullmore ET, Brammer M, Gray JA: **Neural responses to facial and vocal expressions of fear and disgust.** *Proc R Soc London Ser B* 1998, **265**:1809-1817.
41. Hariri AR, Bookheimer SY, Mazziotta JC: **Modulating emotional responses: effects of a neocortical network on the limbic system.** *Neuroreport* 2000, **11**:43-48.
42. Kapler ES, Hariri AR, Mattay VS, McClure RK, Weinberger DR: **Correlated attenuation of amygdala and autonomic responses: a simultaneous fMRI and SCR study.** *Soc Neurosci Abstr* 2001, **645**:3.
43. Critchley HD, Daly E, Phillips M, Brammer M, Bullmore E, Williams S, van Amelsvoort T, Robertson D, David A, Murphy D: **Explicit and implicit neural mechanisms for processing of social information from facial expressions: a functional magnetic imaging study.** *Hum Brain Map* 2000, **9**:93-105.
- The authors of this study compare explicit judgements of emotional facial expressions (happy and angry versus neutral) with implicit processing, when gender judgements were made about the same stimuli. Viewing facial expressions of emotion activated the pulvinar, fusiform gyrus, and amygdala. Explicit emotion judgements resulted in greater activation of temporal neocortex than gender judgements. However, they resulted in less activation in amygdala, suggesting a role for the amygdala in implicit, automatic emotion processing.

44. Morris JS, Oehman A, Dolan RJ: **Conscious and unconscious emotional learning in the human amygdala.** *Nature* 1998, **393**:467-470.
45. Wright CI, Fischer H, Whalen PJ, Mclnerney SC, Shin LM, Rauch SL: **Differential prefrontal cortex and amygdala habituation to repeatedly presented emotional stimuli.** *Neuroreport* 2001, **12**:379-383.
46. Phillips ML, Medford N, Young AW, Williams L, Williams SC, Bullmore ET, Gray JA, Brammer MJ: **Time courses of left and right amygdala responses to fearful facial expressions.** *Hum Brain Map* 2001, **12**:193-202.
47. Thomas KM, Drevets WC, Whalen PJ, Eccard CH, Dahl RE, Ryan ND, Casey BJ: **Amygdala response to facial expressions in children and adults.** *Biol Psychiatry* 2001, **49**:309-316.
48. Killgore WD, Oki M, Yurgelun-Todd DA: **Sex-specific developmental changes in amygdala responses to affective faces.** *Neuroreport* 2001, **12**:427-433.
49. Iidaka T, Okada T, Murata T, Omori M, Kosaka H, Sadato N, Yonekura Y: **An fMRI study of age-related differences in the medial temporal lobe responses to emotional faces.** *Soc Neurosci Abstr* 2001, **550**:3.
50. Hornak J, Rolls ET, Wade D: **Face and voice expression identification in patients with emotional and behavioral changes following ventral frontal lobe damage.** *Neuropsychologia* 1996, **34**:247-261.
51. Vuilleumier P, Armony JL, Driver J, Dolan RJ: **Effects of attention and emotion on face processing in the human brain. An event-related fMRI study.** *Neuron* 2001, **30**:829-41.
- Here, subjects were shown neutral and afraid facial expressions under various attentional conditions. The authors find that effects of facial emotion are found in the right fusiform gyrus, left amygdala, superior colliculi, and right orbitofrontal cortex. Most interesting was an interaction between attention and emotion response in fusiform gyrus, but not in amygdala, suggesting that amygdala activation is not modified by attention, whereas fusiform gyrus activation is.
52. Nakamura K, Kawashima R, Ito K, Sugiura M, Kato T, Nakamura A, Hatano K, Nagumo S, Kubota K, Fukuda H *et al.*: **Activation of the right inferior frontal cortex during assessment of facial emotion.** *J Neurophysiol* 1999, **82**:1610-1614.
53. Narumoto J, Yamada H, Iidaka T, Sadato N, Fukui K, Itoh H, Yonekura Y: **Brain regions involved in verbal or non-verbal aspects of facial emotion recognition.** *Neuroreport* 2000, **11**:2571-2576.
54. Harmer CJ, Thilo KV, Rothwell JC, Goodwin GM: **Transcranial magnetic stimulation of medial-frontal cortex impairs the processing of angry facial expressions.** *Nat Neurosci* 2001, **4**:17-18.
- Harmer *et al.* provide one of the first examples of transcranial magnetic stimulation to disrupt emotion recognition. Disruption within medial frontal cortex results in a subtle increase in reaction times, when identifying morphs of angry facial expressions, but not of happy facial expressions, consistent with the role of this brain region in processing emotions related to anger.
55. Blair RJR, Morris JS, Frith CD, Perrett DI, Dolan RJ: **Dissociable neural responses to facial expressions of sadness and anger.** *Brain* 1999, **122**:883-893.
56. Marinkovic K, Trebon P, Chauvel P, Halgren E: **Localized face processing by the human prefrontal cortex: face-selective intracerebral potentials and post-lesion deficits.** *Cognit Neuropsychol* 2000, **17**:187-199.
57. Kawasaki H, Adolphs R, Kaufman O, Damasio H, Damasio AR, Granner M, Bakken H, Hori T, Howard MA: **Single-unit responses to emotional visual stimuli recorded in human ventral prefrontal cortex.** *Nat Neurosci* 2001, **4**:15-16.
58. Adolphs R, Damasio H, Tranel D, Cooper G, Damasio AR: **A role for somatosensory cortices in the visual recognition of emotion as revealed by 3-D lesion mapping.** *J Neurosci* 2000, **20**:2683-2690.
- Here, we studied 108 patients with focal brain damage and examined the overlaps of their lesions as a function of their ability to recognize emotions. Lesions in right somatosensory related cortices, including primary and secondary somatosensory areas, insula and anterior supramarginal gyrus, as well as lesions in the left frontal operculum, resulted in the worst performance on a task of emotion recognition.
59. Wild B, Erb M, Bartels M: **Are emotions contagious? Evoked emotions while viewing emotionally expressive faces: quality,**

- quantity, time course and gender differences. *Psychiatry Res* 2001, **102**:109-124.
60. Harmer CJ, Perrett DI, Cowen PJ, Goodwin GM: **Administration of the beta-adrenoceptor blocker propranolol impairs the processing of facial expressions of sadness.** *Psychopharmacology* 2001, **154**:383-389.
61. Phillips ML, Young AW, Senior C, Brammer M, Andrew C, Calder AJ, Bullmore ET, Perrett DI, Rowland D, Williams SCR *et al.*: **A specific neural substrate for perceiving facial expressions of disgust.** *Nature* 1997, **389**:495-498.
62. Sprengelmeyer R, Rausch M, Eysel U, Przuntek H: **Neural structures associated with recognition of facial expressions of basic emotions.** *Proc R Soc London Ser B* 1998, **265**:1927-1931.
63. Calder AJ, Keane J, Manes F, Antoun N, Young AW: **Impaired recognition and experience of disgust following brain injury.** *Nat Neurosci* 2000, **3**:1077-1078.
- A patient with damage to left basal ganglia and left insula was impaired not only in his ability to recognize facial expressions of disgust, but also in his ability to experience disgust. This finding is consistent with the role of these two structures in processing information about disgust, as corroborated by functional imaging studies. However, it does not yet tell us if both the basal ganglia and insula are critical for emotion recognition, or if damage to one of the two structures is sufficient to cause the observed impairment.
64. Adolphs R, Tranel D, Damasio AR: **Dissociable neural systems for recognizing emotions.** *Brain Cognit* 2002, in press.
- Here, we report the case of a patient with extensive bilateral temporal lobe damage, as well as damage to the insula, who was severely impaired in recognizing emotions from facial expressions. He was only able to recognize basic emotions at the superordinate level of 'pleasant'/'unpleasant', and he was most severely impaired in recognition of disgust.
65. Sprengelmeyer R, Young AW, Pundt I, Sprengelmeyer A, Calder AJ, Berrios G, Winkel R, Vollmoeller W, Kuhn W, Sartory G *et al.*: **Disgust implicated in obsessive-compulsive disorder.** *Proc R Soc London Ser B* 1997, **264**:1767-1773.
66. Adolphs R, Schul R, Tranel D: **Intact recognition of facial emotion in Parkinson's disease.** *Neuropsychology* 1997, **12**:253-258.
67. Sprengelmeyer R, Young AW, Calder AJ, Karnat A, Lange H, Hoemberg V, Perrett DI, Rowland D: **Loss of disgust. Perception of faces and emotions in Huntington's disease.** *Brain* 1996, **119**:1647-1666.
68. Gray JM, Young AW, Barker WA, Curtis A, Gibson D: **Impaired recognition of disgust in Huntington's disease gene carriers.** *Brain* 1997, **120**:2029-2038.
69. Anderson AK, Phelps EA: **Lesions of the human amygdala impair enhanced perception of emotionally salient events.** *Nature* 2001, **411**:305-309.
- Although normal individuals show an effect on the attentional blink when presented with emotionally arousing stimuli (words, in this study), damage to the amygdala blocked this modulation by emotionally arousing stimuli. This finding shows that attentional processes that may be implemented in relatively low-level structures such as visual cortex could be modulated by structures such as the amygdala, perhaps via feedback.
70. Scherer KR, Banse R, Wallbot HG, Goldbeck T: **Vocal cues in emotion encoding and decoding.** *Motiv Emotion* 1991, **15**:123-148.
71. Morris JS, Scott SK, Dolan RJ: **Saying it with feeling: neural responses to emotional vocalizations.** *Neuropsychologia* 1999, **37**:1155-1163.
72. Buchanan TW, Lutz K, Mirzazade S, Specht K, Shah NJ, Zilles K, Jancke L: **Recognition of emotional prosody and verbal components of spoken language: an fMRI study.** *Cognit Brain Res* 2000, **9**:227-238.
73. Rama P, Martinkauppi S, Linnankoski I, Koivisto J, Aronen HJ, Carlson S: **Working memory of identification of emotional vocal expressions: an fMRI study.** *Neuroimage* 2001, **13**:1090-1101.
74. Pell MD: **Recognition of prosody following unilateral brain lesion: influence of functional and structural attributes of prosodic contours.** *Neuropsychologia* 1998, **36**:701-715.
75. Ross ED, Stark RD, Yenkosky JP: **Lateralization of affective prosody in brain and the callosal integration of hemispheric language functions.** *Brain Lang* 1997, **56**:27-54.
76. Belin P, Zatorre RJ, Lafaille P, Ahad P, Pike B: **Voice-selective areas in human auditory cortex.** *Nature* 2000, **403**:309-312.
77. Barrett AM, Crucian GP, Raymer AM, Heilman KM: **Spared comprehension of emotional prosody in a patient with global aphasia.** *Neuropsychiatry Neuropsychol Behav Neurol* 1999, **12**:117-120.
78. Wessinger CM, Van Meter J, Tian B, Van Lare J, Pekar J, Rauschecker JP: **Hierarchical organization of the human auditory cortex revealed by functional magnetic resonance imaging.** *J Cognit Neurosci* 2001, **13**:1-7.
79. Tian B, Reser D, Durham A, Kustov A, Rauschecker JP: **Functional specialization in rhesus monkey auditory cortex.** *Science* 2001, **292**:290-293.
80. Adolphs R, Damasio H, Tranel D: **Neural systems for recognizing emotional prosody.** *Emotion* 2002, in press.
- Using an analysis identical to that used with facial expressions [58*], we show that right frontoparietal cortex is critical to recognizing emotion from prosody. Additionally, the study reveals that the left frontal operculum and bilateral frontal polar cortex (area 10) are important in the recognition of emotion from prosody. The findings also provide support for the hypothesis that emotion recognition proceeds, in part, via the construction of a simulation of the emotion in the perceiver.
81. Breitenstein C, Daum I, Ackermann H: **Emotional processing following cortical and subcortical brain damage: contribution of the fronto-striatal circuitry.** *Behav Neurology* 1998, **11**:29-42.
82. Blood AJ, Zatorre RJ, Bermudez P, Evans AC: **Emotional responses to pleasant and unpleasant music correlate with activity in paralimbic brain regions.** *Nat Neurosci* 1999, **2**:382-387.
83. Frey S, Kostopoulos P, Petrides M: **Orbitofrontal involvement in the processing of unpleasant auditory information.** *Eur J Neurosci* 2000, **12**:3709-3712.
84. Scott SK, Young AW, Calder AJ, Hellawell DJ, Aggleton JP, Johnson M: **Impaired auditory recognition of fear and anger following bilateral amygdala lesions.** *Nature* 1997, **385**:254-257.
85. Royet JP, Zald D, Versace R, Costes N, Lavenne F, Koenig O, Gervais R: **Emotional responses to pleasant and unpleasant olfactory, visual, and auditory stimuli: a positron emission tomography study.** *J Neurosci* 2000, **20**:7752-7759.
- The authors of this study report that amygdala activation was not obtained when emotionally arousing stimuli in the auditory or visual modality were used, but robust amygdala activation was obtained with emotionally arousing olfactory stimuli.
86. Anderson AK, Phelps EA: **Intact recognition of vocal expressions of fear following bilateral lesions of the human amygdala.** *Neuroreport* 1998, **9**:3607-3613.
87. Adolphs R, Tranel D: **Intact recognition of emotional prosody following amygdala damage.** *Neuropsychologia* 1999, **37**:1285-1292.
88. Rolls ET: *The Brain and Emotion.* New York: Oxford University Press; 1999.
89. Zald DH, Pardo JV: **Emotion, olfaction, and the human amygdala: amygdala activation during aversive olfactory stimulation.** *Proc Natl Acad Sci* 1997, **94**:4119-4124.
90. Hudry J, Ryvlin P, Royet JP, Maugeire F: **Odorants elicit evoked potentials in the human amygdala.** *Cereb Cortex* 2001, **11**:619-627.
91. Zald DH, Lee JT, Fluegel KW, Pardo JV: **Aversive gustatory stimulation activates limbic circuits in humans.** *Brain* 1998, **121**:1143-1154.
92. Rolls ET, Francis S, Bowtell R, Browning AS, Clare S, Smith E, McGlone F: **Pleasant touch activates the orbitofrontal cortex.** *Neuroimage* 1997, **5**:S17.
93. McClure EB: **A meta-analytic review of sex differences in facial expression processing and their development in infants, children, and adolescents.** *Psychol Bull* 2000, **126**:424-253.
94. Panksepp J: *Affective Neuroscience.* New York: Oxford University Press; 1998.
95. Rapcsak SZ, Galper SR, Comer JF, Reminger SL, Nielsen L, Kaszniak AW, Verfaellie M, Laguna JF, Labiner DM, Cohen RA: **Fear recognition deficits after focal brain damage.** *Neurology* 2000, **54**:575-581.
- In a study of a large number of brain-damaged and normal individuals, the authors find that recognition of fear was the most difficult task even for normal subjects. The incorporation of this level of difficulty into the analysis showed that lesions in many regions, previously reported to result in specific impairments in fear recognition, did not actually give such specific impairments.

However, the study used a particular task, in which subjects were asked to match the facial expression to a list of labels for the emotions; this task makes fear a more difficult choice because it provides an ambiguous set of labels for it: fear and surprise. If a different task is used, this problem can be circumvented. This study highlights the importance of experimental design and analysis for the interpretation of emotion recognition.

96. Peretz I: **Brain specialization for music. New evidence from congenital amusia.** *Ann N Y Acad Sci* 2001, **930**:153-165.
97. Blood AJ, Zatorre RJ: **Intensely pleasurable responses to music correlate with activity in brain regions implicated in reward and emotion.** *Proc Natl Acad Sci USA* 2001, **98**:11818-11823.
98. Kampe KKW, Frith CD, Dolan RJ, Frith U: **Reward value of attractiveness and gaze.** *Nature* 2001, **413**:589.
99. Aharon I, Etcoff NL, Ariely D, Chabris CF, O'Connor E, Breiter HC: **Beautiful faces have variable reward value: fMRI and behavioral evidence.** *Neuron* 2001, **32**:537-551.